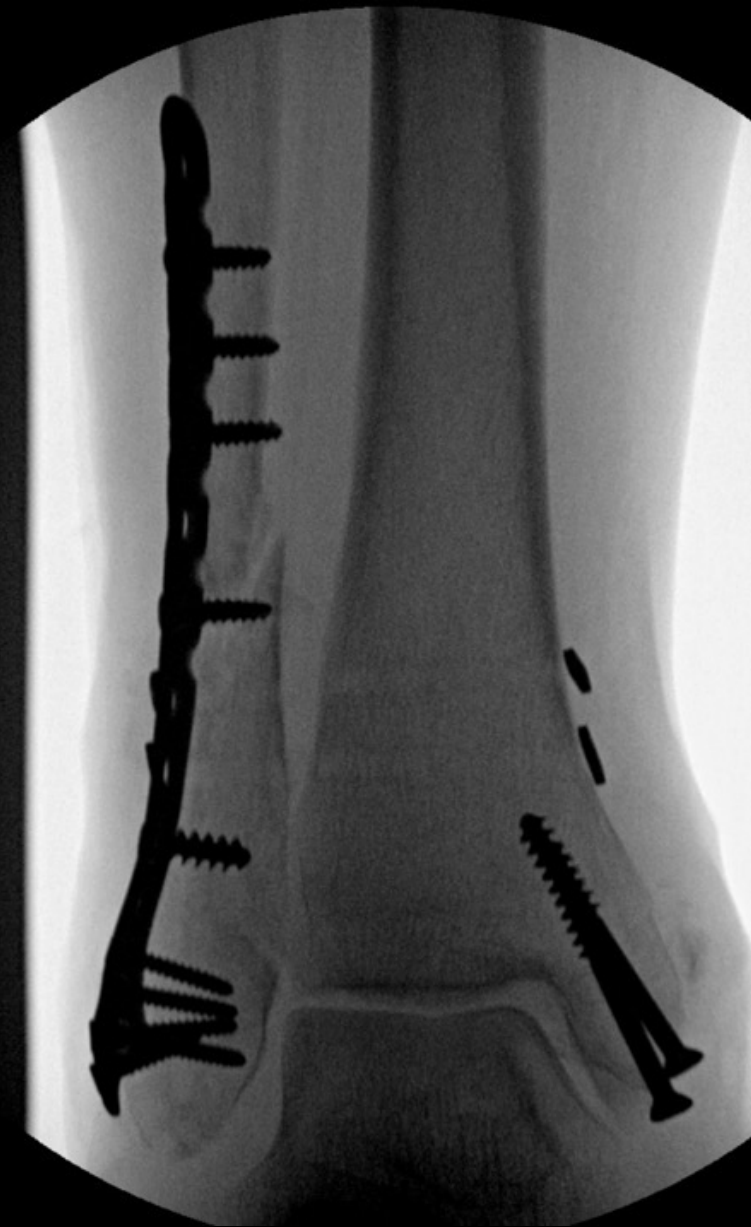
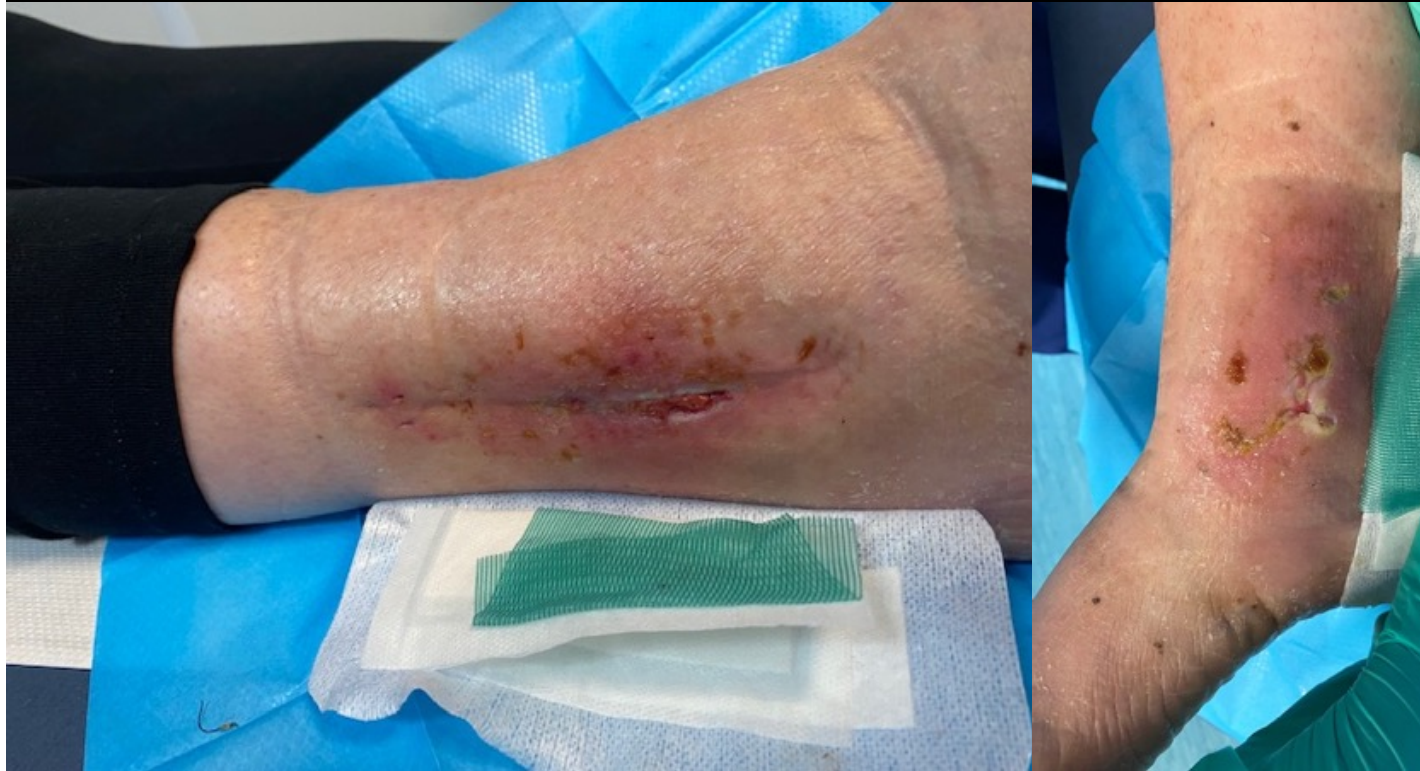
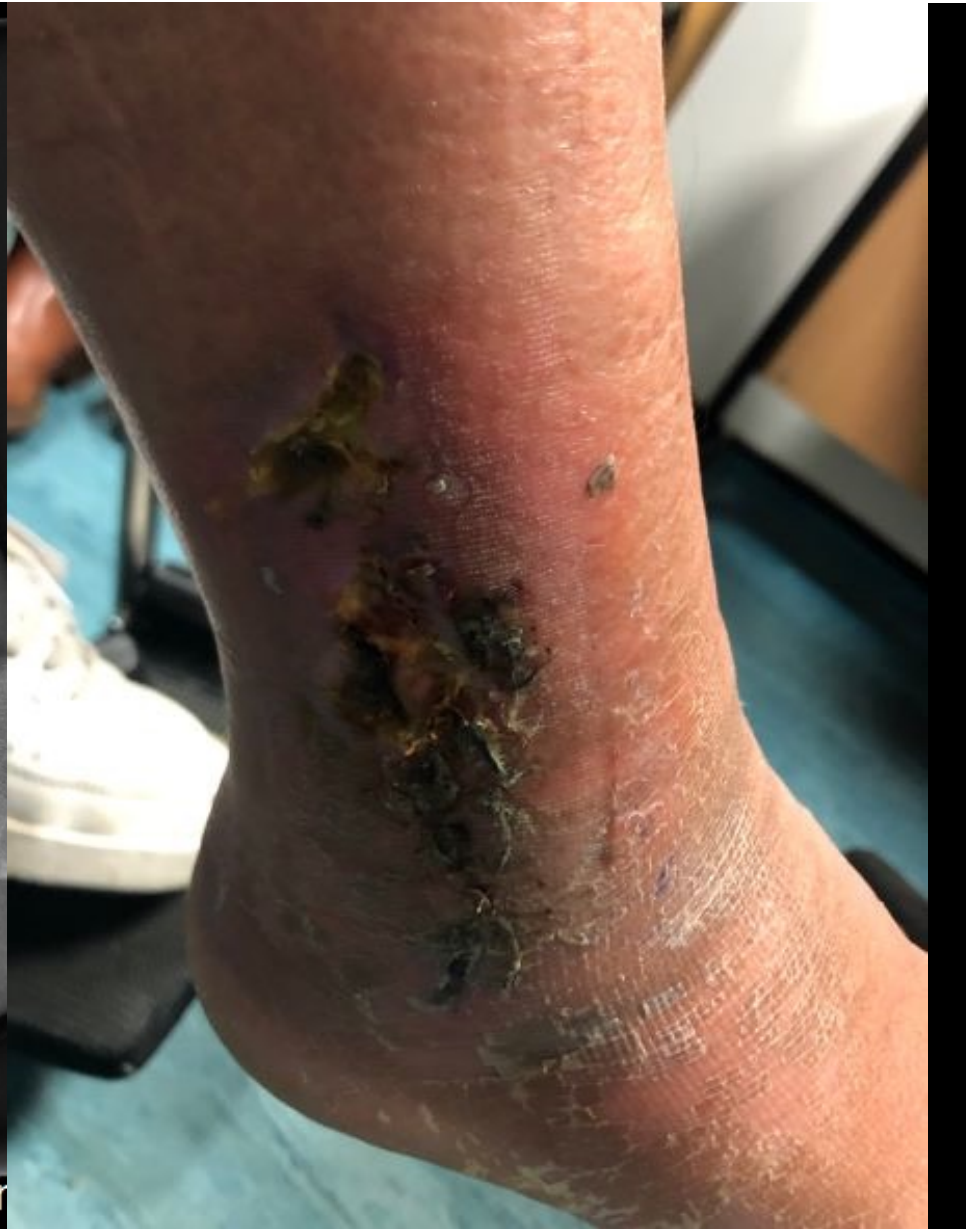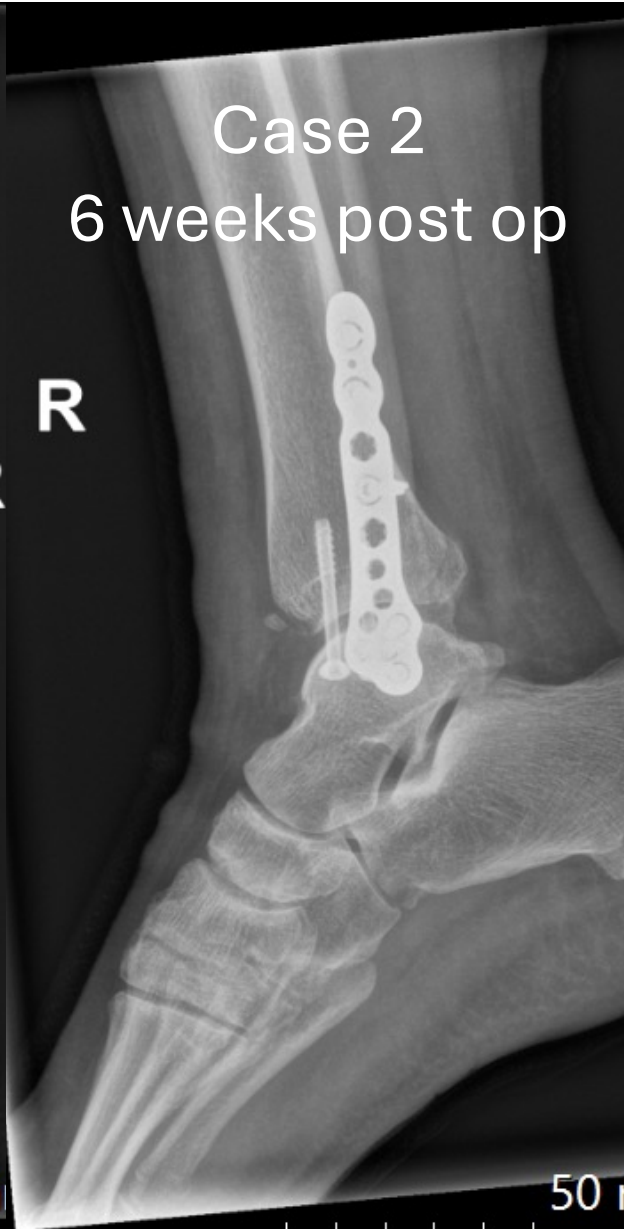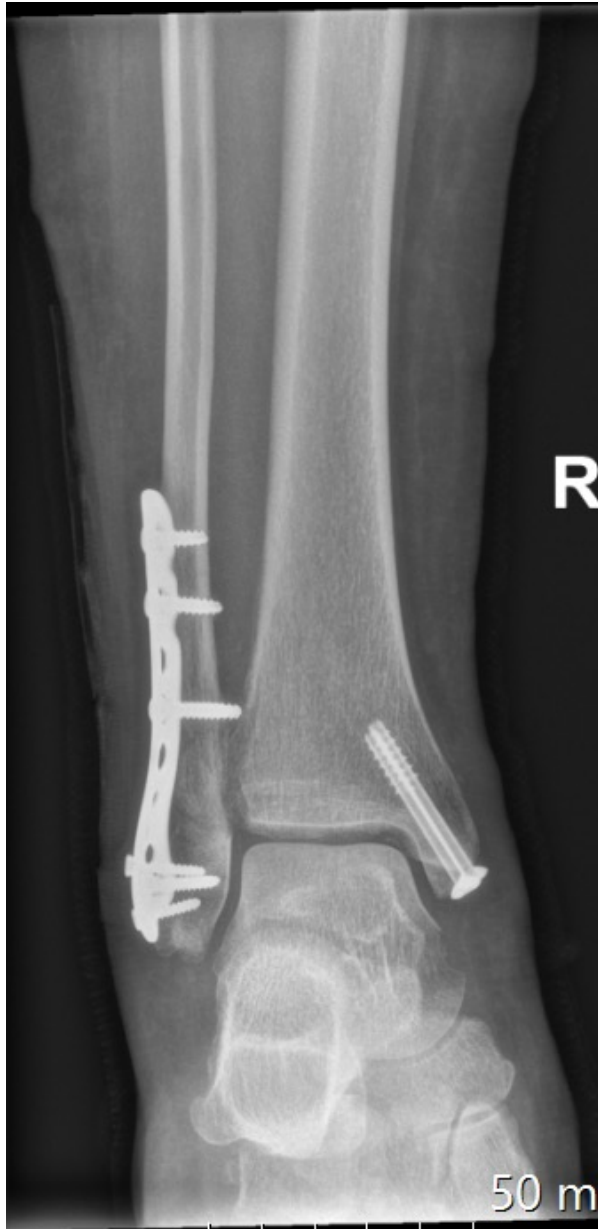# Fracture Related Infection cases

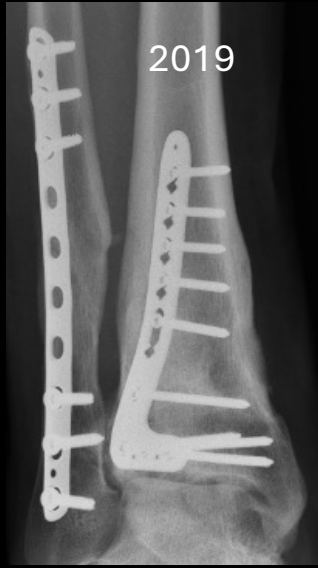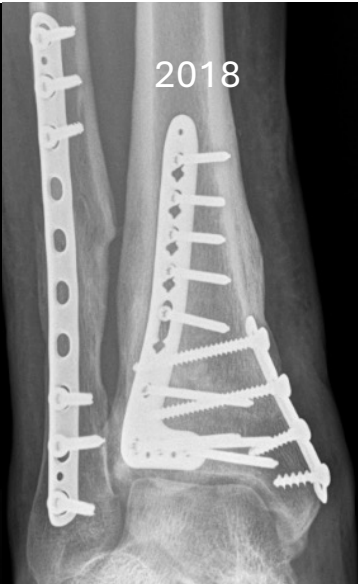- 68yr female
- Hypertension
- Psoriatic arthropathy

## Case 1 3 weeks post op



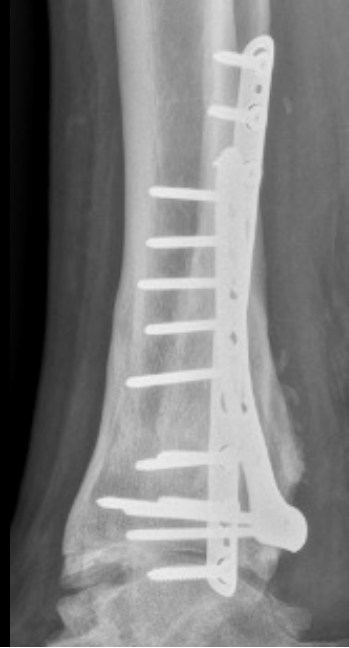
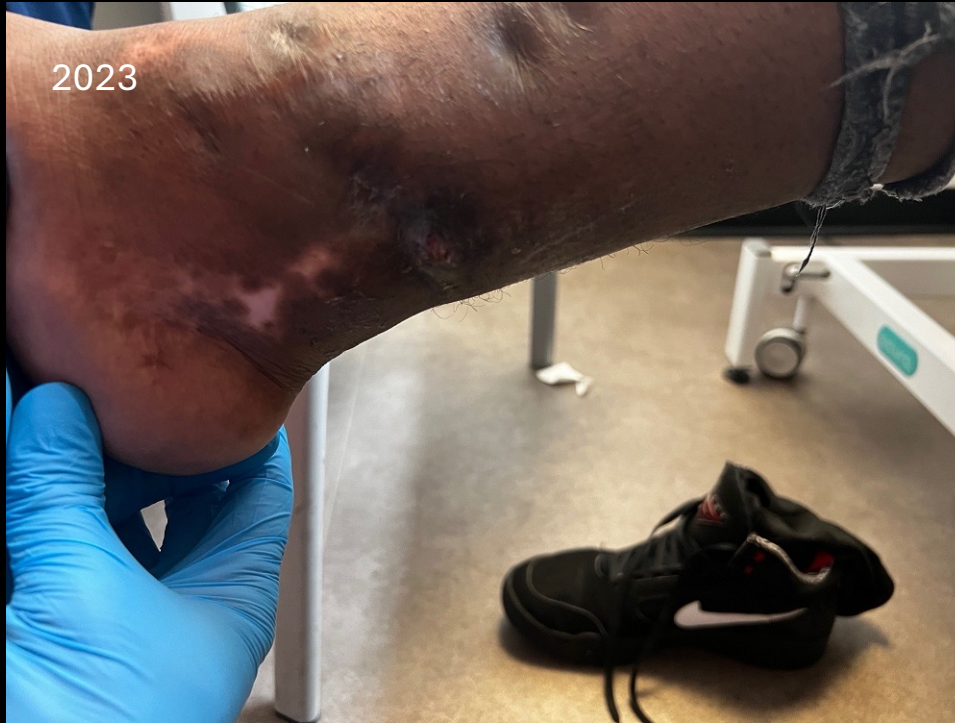
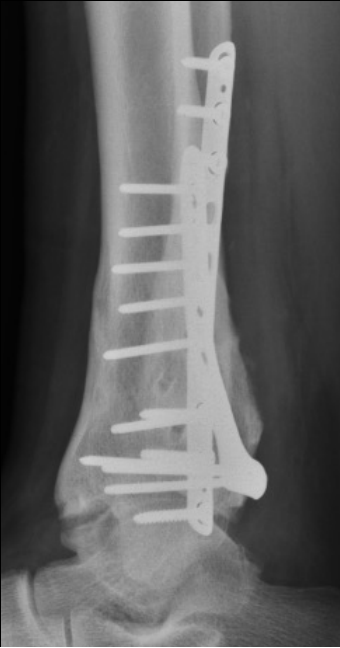
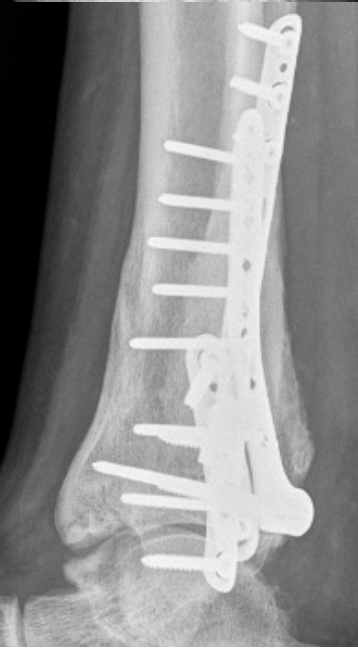
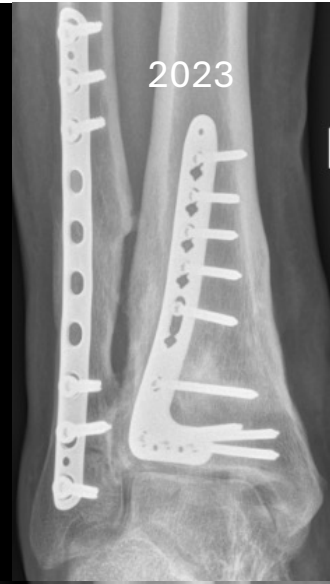

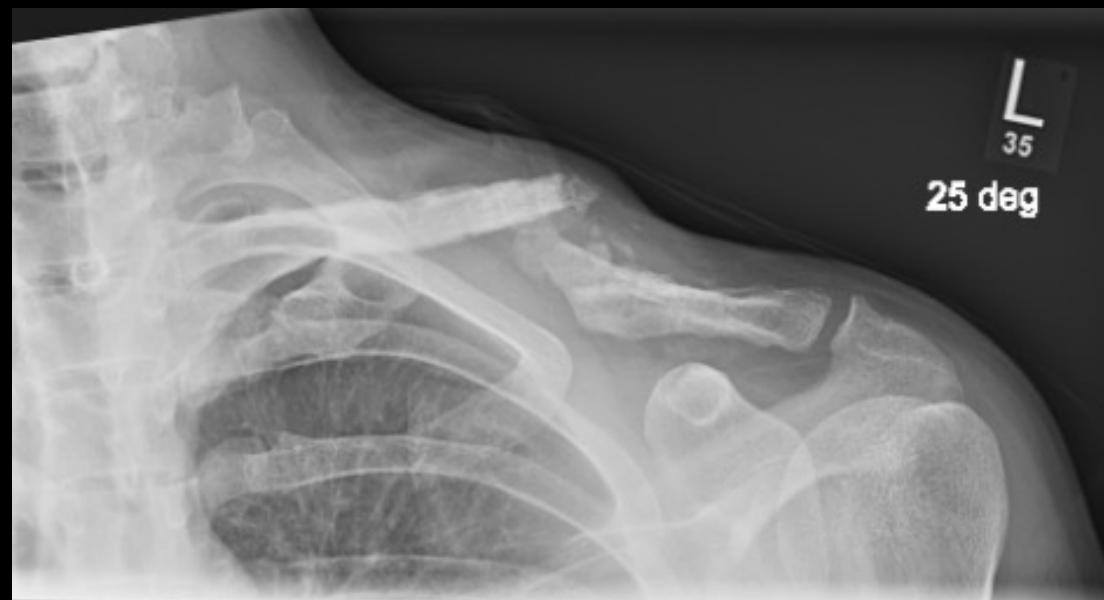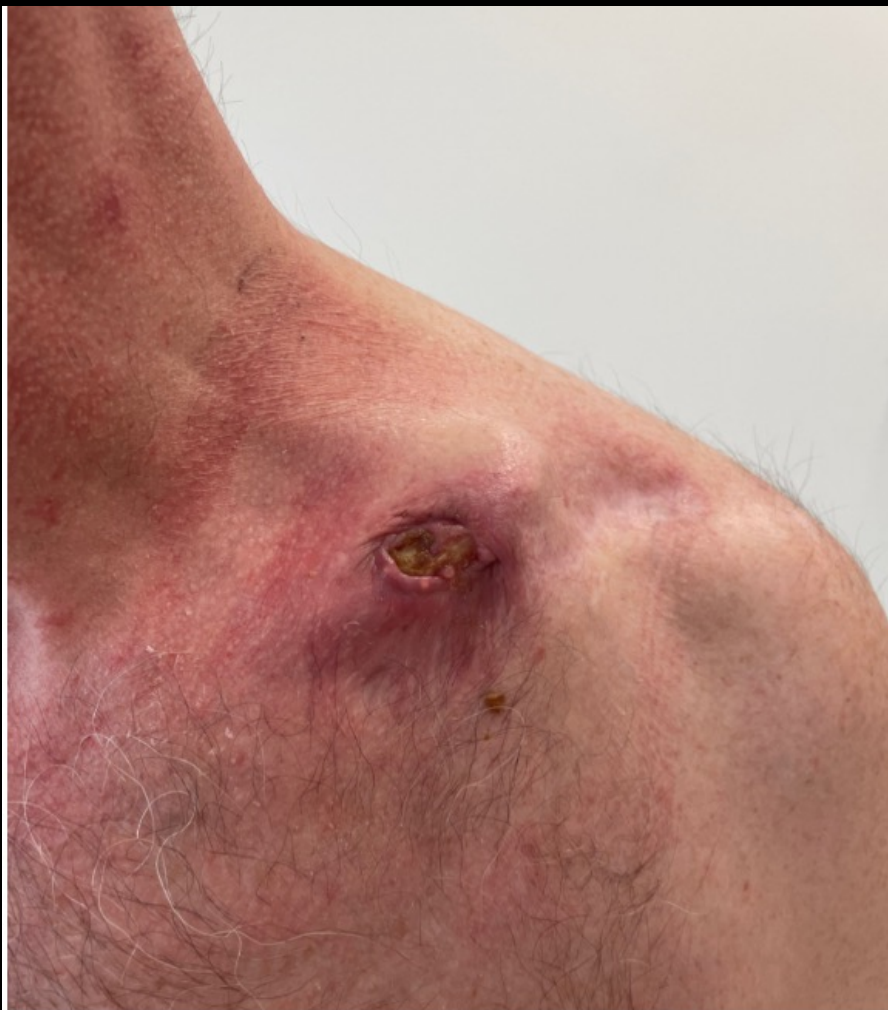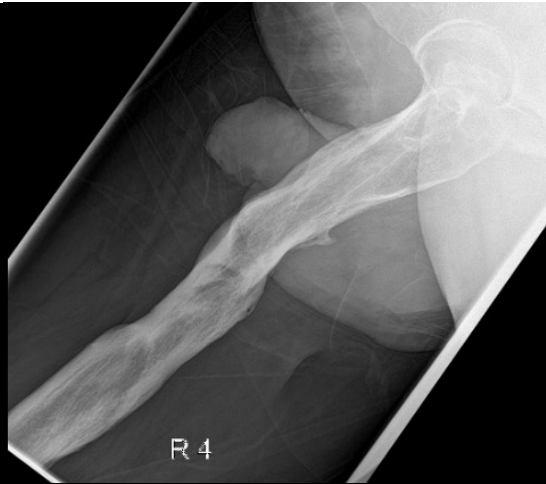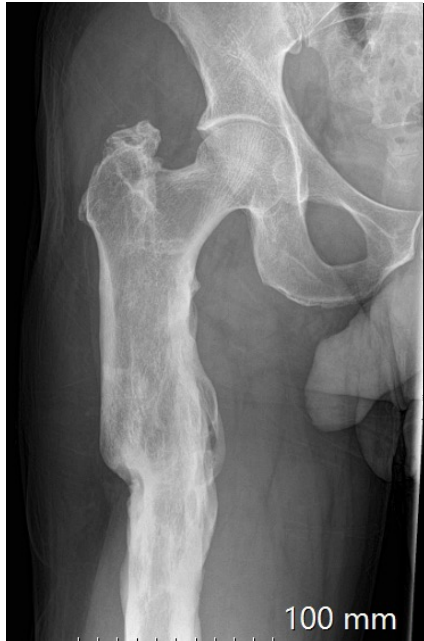## Case 3

Posteromedial sinus  
Medial plate removed in 2019



## Case 4

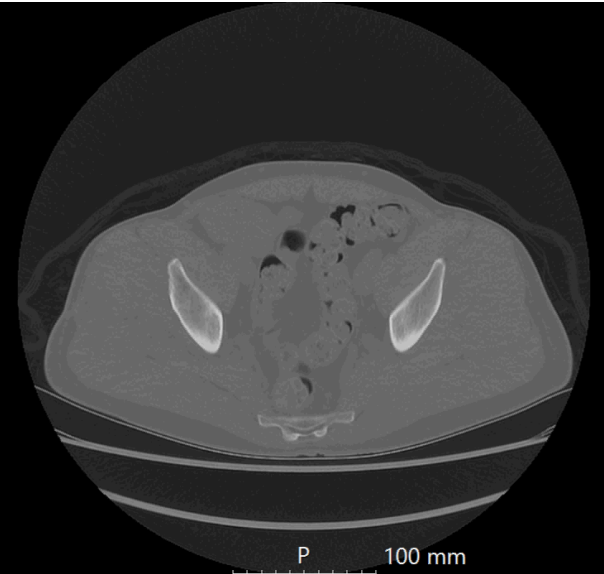
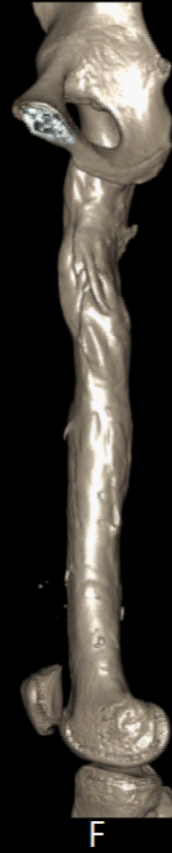
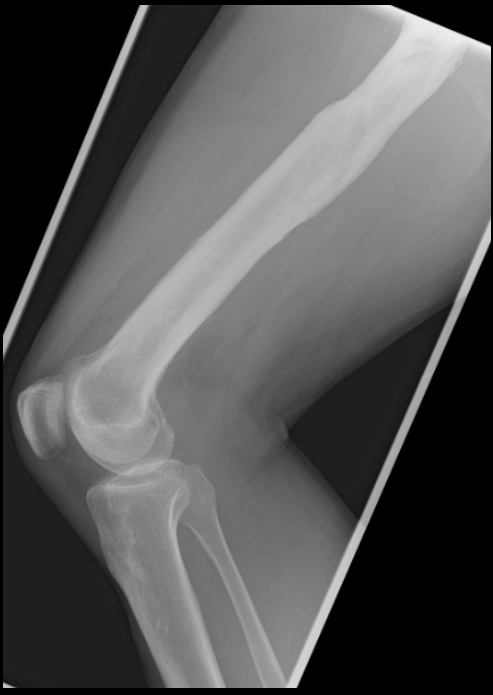
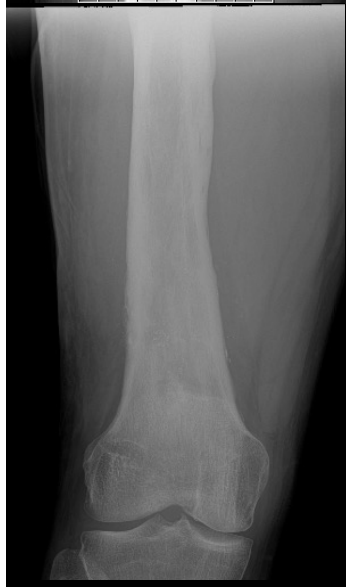

Case 5

23 yrs ago infected femoral nail removed

Abscess posterior aspect mid-thigh



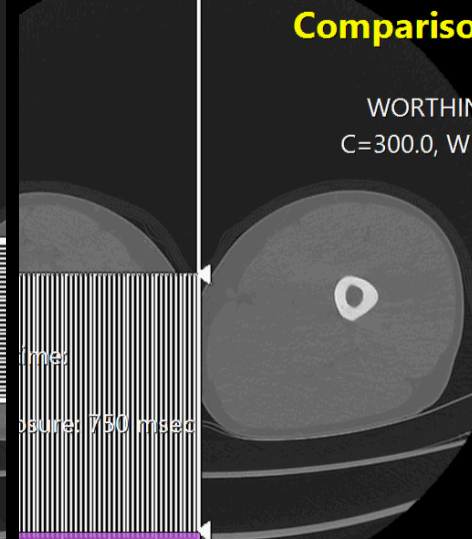
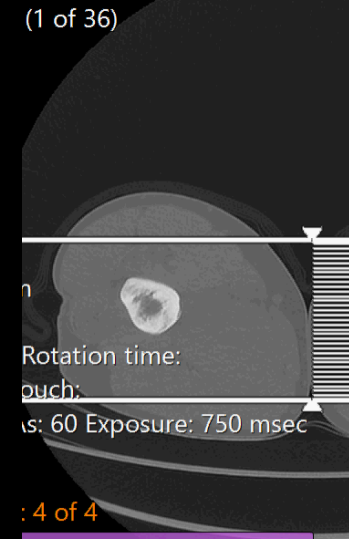
Standard RIGHT/Coronal.Ref (1 of 36)

RIGHT/Sagittal.Ref

C: 300.0

Comparison

WORTHING C=300.0, W=



: 4 of 4

2018, 12:10:08

2:10:08



Case 6  
3 months post  
revision fixation

